

REPRODUCTIVE OUTCOME, DURATION OF PREGNANCY AND MODE OF DELIVERY AFTER HYSTEROSCOPIC METROPLASTY IN PATIENTS WITH INFERTILITY

Tofoski Gligor, Dimitrov Goran, Hadzi Lega Marija, Dzikova Elena

PHI University Clinic of Gynecology and Obstetrics, Medical Faculty,
University "St. Cyril and Methodius" - Skopje, Republic of Macedonia

Primljen/Received 20. 05. 2016. god.

Prihvaćen/Accepted 22. 06. 2016. god.

Abstract: Introduction: Reproductive outcome can be negatively affected in patients with congenital uterine anomalies (CUA), increasing the number of unsuccessful pregnancies and obstetric complications. Standard, safe and minimally invasive method for the treatment of correctible types of congenital uterine anomalies is hysteroscopic metroplasty (HM).

The aim of the study was to analyze the reproductive outcome, duration of pregnancy and mode of delivery in group of patients with infertility after hysteroscopic metroplasty.

Material and methods: We analyzed 48 patients with previous history of fetal loss (abortion) to whom hysteroscopy was done in the period of 01. 11. 2009 to 01. 05. 2013 year at the University Clinic of Obstetrics and Gynecology in Skopje. In patients who were diagnosed having CUA hysteroscopic metroplasty was done. Patients and their reproductive outcome were followed for a period of at least 2 years after the intervention. Reproductive outcome was followed considering pregnancy rate, fetal loss (abortion) up to 22 gestational week, rates of preterm and term deliveries, live births and mode of delivery. Statistical analysis was performed using computer software and value for the confidence interval (\pm 95% CI) was considered to be statistically significant with level of $p < 0.05$.

Results: After hysteroscopic metroplasty, there was a significant decrease of the abortion rate to 13.9%, and significant increase in pregnancy rates of 86.1%. Overall pregnancy rate was 75%, and term delivery was noted in 93,6% of the patients, with spontaneous deliveries in 58,6%. There were no complications during the hysteroscopic metroplasty, nor during the deliveries.

Conclusion: Hysteroscopic metroplasty has a significant effect on the reproductive outcome, resulting

in a large number of live births and no significant complication during consecutive pregnancy and delivery.

Keywords: hysteroscopy, metroplasty, reproduction, infertility, pregnancy, delivery.

INTRODUCTION

Congenital anomalies of the female reproductive system (Mullerian anomalies) represent a heterogeneous group of malformations of the genital tract, which can involve uterus, cervix, vagina and Fallopian tubes (1). Majority of reproductive system anomalies can seriously influence the reproductive and obstetric health of women depending on the specificity of the anomaly. They increase the rate of abortions, preterm deliveries, and obstetric complications. Patients with uterine malformations have decreased reproductive potential and unfavorable reproductive outcome. Overall term pregnancy rate in patients with untreated uterine malformations is around 50%. Term delivery rate in pregnant patients with untreated septate and bicornuate uterus is ~40%, and in patients with arcuate uterus reproductive outcome is slightly better, with term delivery rate of ~65% (2). Uterine septum is the most present anomaly in patients with infertility, and possibly the most prone to a surgical correction (3, 4).

Etiology of CUA is not completely explained, majority of patients having normal karyotype, and some environmental, pharmacological and genetics factors might have some influence. Most probably its origin is polygenic or multifactorial (5). Several classifications were made in order to optimize the diagnosis and treatment of those anomalies. The classification of the anomalies of the female reproductive system depending on the degree of failure of normal development, in groups of similar clinical manifestations, treatment and progno-

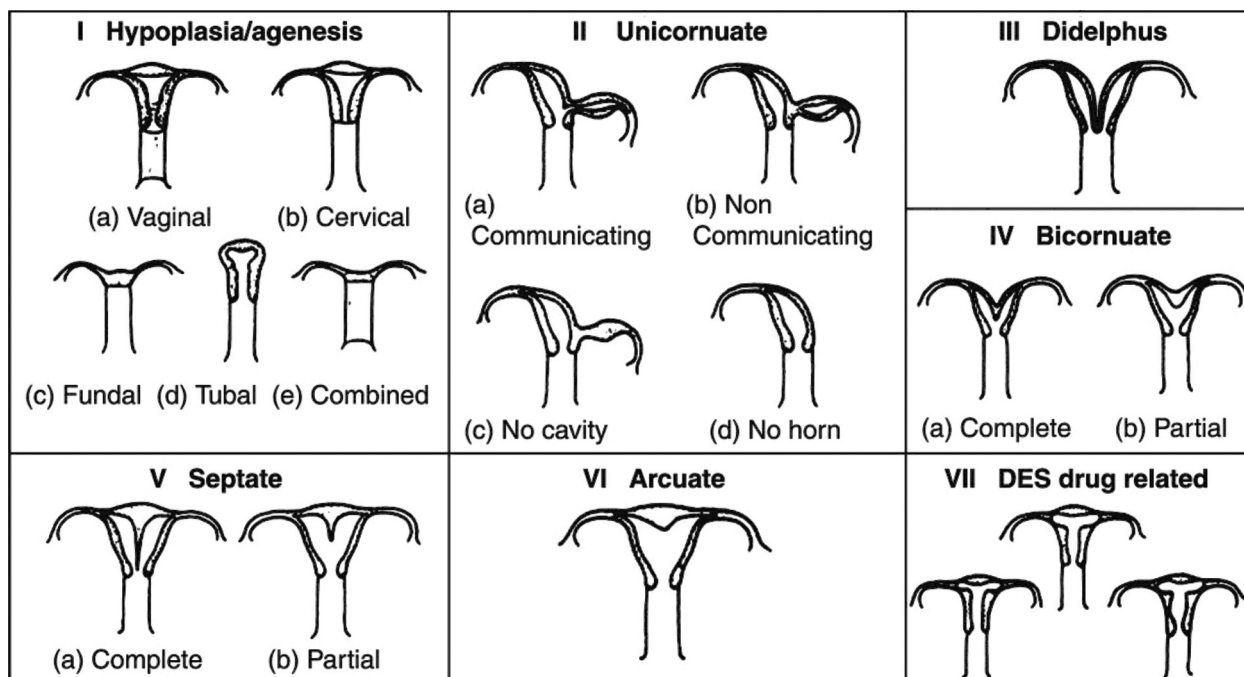


Figure 1. Schematic presentation of AFS classification

sis for their reproductive outcome, had the most clinical practice and was adopted by the American Fertility Society (AFS) in 1988 (6), and is used worldwide (Figure 1).

Uterine cavity abnormality is considered to be one of the factors which influence the reproductive outcome of these patients. A surgical correction by hysteroscopic metroplasty (HM) has all the benefits of a good operative treatment: decreased intra- and postoperative morbidity, short-time intervention, less analgesic requirements, shorter hospital stay, shorter interval to conception and possibility for a vaginal delivery (7).

It provides anatomically normal uterine cavity, but does not certainly result in a favorable reproductive outcome since uterine vascularization is probably involved in the uterine function. The theory which is nowadays widely accepted, states that septum is consisted of fibroelastic tissue with inadequate vascularization and changed ratio between blood vessels of the endometrium and myometrium, presenting negative effects on decidualisation and placentation (8).

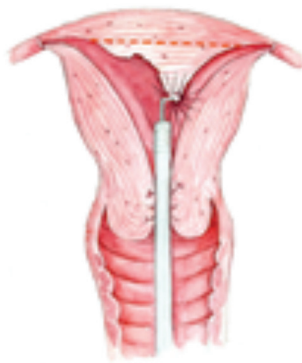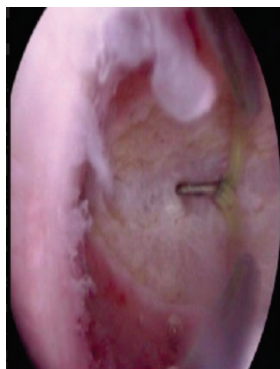


Figure 2. Hysteroscopic metroplasty in uterus septus

Majority of uterine malformations (> 55%) are presented with septate and arcuate uterus (type 5 and 6 according to AFS classification), which can be effectively treated by means of operative hysteroscopy. Partial reconstruction of the uterine cavity by hysteroscopy is possible in some cases of partial bicornuate uterus (type 4b). Hysteroscopic metroplasty obtains normal uterine cavity, but also resolves normal uterine function, by providing normal reproductive outcome in these patients (9, 10, 11) (Figure 2).

The results of some studies suggest that patients who underwent hysteroscopic metroplasty are at no higher risk of adverse obstetric outcome at term and during labor, comparing to the general population. (12). Several studies reported an increased incidence of premature labor in patients who underwent dilatation and curettage or conceived after a long time of infertility (13, 14). Though vaginal delivery seems to be safe, rare but serious complication reported, like uterine rupture during pregnancy or labor, should always be taken into consideration.

The aim of the study was to analyze the reproductive outcome, duration of pregnancy and mode of delivery in group of patients with infertility after hysteroscopic metroplasty.

MATERIAL AND METHODS

We analyzed 48 patients with infertility to whom hysteroscopic metroplasty (HM) was performed at the University Clinic of Obstetrics and Gynecology in Skopje, during the period between 01. 11. 2009 to 01. 05. 2013. Inclusion criteria for the study was diagnosis of uterine malformation of correctible types (4b, 5a, 5b and

6), according to the AFS classification, and exclusion criteria were existence of other intrauterine pathology (submucous myoma, polyp, etc.). Patients and their reproductive outcome were monitored during a two-year period and the same group served as a control group for themselves, taking into account their previous reproductive history. Hysteroscopic metroplasty was done after the patient previously signed informed consent.

Intervention was done with endoscopic equipment (Olympus and Storz types), using a rigid hysteroscope of 5.5 mm and a resectoscope of 8 and 9 mm, in general anesthesia and sterile conditions. A mixed solution Ispiro® (solution of 2.7% sorbitol and 0.54% manitol) or NaCl 0,9% solution, sterile and apyrogenic served as a distension media.

Hysteroscopic metroplasty (resection of the septum) starts in the midline between the anterior and posterior uterine wall and continues cranially towards the end point. End point is the moment when the following has been achieved: hysteroscope can move freely from one to the other ostium without obstruction, when both ostia are easily visualized from the upper part of the cavity or when more intensive bleeding starts from the place of the resection as a sign of proximity to the junction between the septum and the myometrium.

The following variables associated with the reproductive outcome were monitored in our group of patients: pregnancy rate, abortion rate, preterm and term delivery rate and the way of delivery. Data were analyzed using the program SPSS for Windows, version 11.0. Statistical analysis was done using Chi-square test and p-value of 0.05 was considered to be statistically significant.

RESULTS

Comparing the number of diagnosed anomalies – the largest number of 35 (72.9%) hysteroscopic metroplasties were done in the group of patients with arcuate uterus (type 6), followed by the group of patients with partial septate uterus (type 5b) - 6 cases (12,5%) and the group of patients with complete septate uterus (type 5a) in 4 patients (8.3%). The least present anomaly was partial bicornuate uterus (type 4b) in 3 cases (6.3%), as we can see in Table 1.

Table 1. Frequency of certain types of CUA

Diagnosed CUA	No.	%
IVb	3	6.3
Va	4	8.3
Vb	6	12.5
VI	35	72.9
Total	48	100.0

As represented in the most of the published literature, congenital uterine anomalies most present were types 5b and 6 - partial septate uterus and arcuate uterus, represented by 85.4%.

None of the patients had complications from the procedure-during hysteroscopy and hysteroscopic metroplasty.

Table 2. Pregnancy after hysteroscopic metroplasty and time period to subsequent pregnancy

Pregnancy	No.	%
No pregnancy	12	25.0
0-6 months	21	43.7
7-12 months	10	20.8
13-24 months	5	10.4
≥ 24 months		
Total	48	100.0

Most of the patient become pregnant during the first 6 months after HM (43.7%), 20.8% in the period between 6-12 months, or overall during the first year 31 patients became pregnant (64.6%). During the two year period 36 patients became pregnant (75%) (Table 2).

Fetal loss up to 22 gestational week (abortion) was noted in 5 of the patients (13.9%), out of which 1 belonged to group IVb, one to group Va, and 3 to the group VI. Pregnancy continued in 31 patients (86.1%).

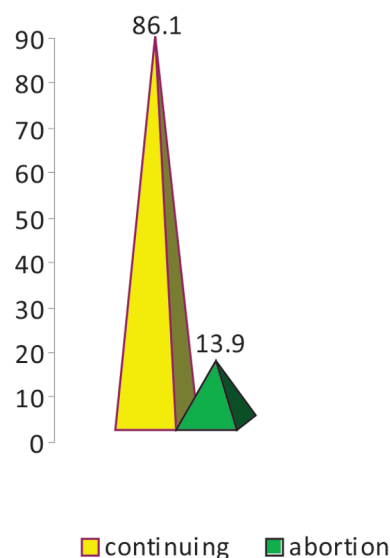


Figure 3. Distribution according to duration of pregnancy up to 22 g.w.

Out of 31 patients who continued their pregnancies above 22 gestational week, only 6.4% had preterm deliveries, while majority of them, 29 (93.6%) had delivery during term, as it is shown in Figure 3 and Table 1. Patients in the group of preterm deliveries belonged to the group IV b and Vb.

Table 3. Distribution according to the gestational week of delivery

Gestational week	Delivery	
	No.	%
29-32	1	3.2
32-36	1	3.2
37-40	29	93.6
Total	31	100.0

The rate of operative delivery- caesarean section is slightly elevated in the group of term deliveries, and comprises of 12 patients (41.4%). In the preterm delivery group all the patients -2 (100%) were delivered by SC, which would be a significant difference if the numbers were not too small (Table 4).

Table 4. Mode of delivery

	Preterm delivery		Term delivery	
	No.	%	No.	%
Spontaneous vaginal	–	–	17	58.6
SC	2	100.0	12	41.4
Total	2	100.0	29	100.0

DISCUSSION

Hysteroscopic metroplasty is surgical intervention for treatment of CUA that are hysteroscopically correctible, which are types 4b (partial bicornuate), 5a (complete septate), 5b (partial septate) and 6 (arcuate uterus).

One of the first published scientific papers made on this topic by Acien in 1993 (15) compared the reproductive outcome in 173 patients with untreated uterine malformation who had 383 pregnancies, and a second group of 28 patients with normal uterus and 47 pregnancies. Abortion rate in patients with uterine malformations was 36%, and preterm delivery rate was 18%, which was significantly higher ($p < 0.01$) than the rate of abortions of 8% and preterm delivery rate of 6% in patients with normal uterus. Term delivery rate in patients with uterine malformations was 44% and live birth rate of 53%, which was lower and statistically significant ($p < 0.001$) from the group with normal uterus where term delivery rate was 85% and live birth rate of 89%.

Analyzing the results from previous studies of Raga, Buttram and Heinonen (3, 16, 17) in a systematic review in 2001, Grimbizis found that in 102 patients with untreated arcuate uterus and number of 241 pregnancies, the abortion rate was 25.8% and prematurity

rate was 7.5%. The rates for term delivery and live birth were 62.7% and 66%, respectively. In the group with untreated septate uterus he found an abortion rate of 44.3% and a preterm delivery rate of 22.4%. After performing hysteroscopic metroplasty, a significant decrease in rates of abortions and preterm delivery was reported in treated patients. Abortion rate decreased to 16.4%, while preterm delivery rate decreased to 6.4%, while a significant rise of term deliveries and live birth was reported (76.3% and 83.2%), in comparison with the rates before the HM that were lower (33% and 50.1%, respectively) (7).

Study of Sendag in 2010 (18) analyzed 30 patients with different degrees of septate uterus, who after one year following hysteroscopic metroplasty had a total of 20 pregnancies. Of these, 11 (55%) were carried to term, two (10%) ended in preterm delivery, seven (35%) ended in spontaneous abortion.

In a study of Nouri in 2010 (19), reproductive outcome was evaluated after hysteroscopic metroplasty in 64 women with septate uterus and primary infertility. Complete follow-up was available for 49/64 (76%) patients, with overall pregnancy rate after HM was 69% (34/49) and overall life birth rate was 49% (24/49).

Roy et al. (20) in the published study in 2011 have analyzed 170 cases with HM during the period of 8.5 years where a significant decrease of unsuccessful pregnancies rate was noted, from 91.5% before metroplasty to 12.5% after metroplasty, and an increase in term delivery rate from 2.5% to 79.5%.

The analysis of our material also showed a significant improvement in the reproductive outcome, which was in agreement with the published medical literature. There was a significant decrease of abortion rate to 13.9%, and a term delivery rate was 93.6%, which is comparable to patients with normal uterus.

There was not an increase of the premature delivery rate in the study group (6.5%). The preterm delivery rate in general population varies between 12 to 13% in the USA and 5 up to 9% in other developed countries (21).

In most of the cases there was a spontaneous vaginal delivery, even though the increase in the rate of caesarean sections was influenced by demand of the patient, or because of the patients previous reproductive history (prolonged period of infertility, previous abortion and operation etc.).

Complications which are published in the literature like rupture of the uterus were not noted in our group of patients (22, 23).

This is a confirmation of the fact that obtaining normal uterine cavity in cases with congenital uterine malformations who have been hysteroscopically corrected, is successfully preparing the uterus for uncomplicated continuation of the pregnancy to term delivery.

CONCLUSION

Congenital uterine anomalies, even minor types of anomalies with small defect of the uterine cavity, have been pointed in several published scientific papers as a uterine factor for a bad reproductive outcome. After treatment with hysteroscopic metroplasty in patients where surgically correctible congenital uterine anomaly exists, a significant improvement of the reproductive outcome in these patients has been reported,

without notable complications during pregnancy or delivery period.

Conflict of interest

Nothing to declare.

Abbreviations

CUA — congenital uterine anomalies

HM — hysteroscopic metroplasty

Sažetak

REPRODUKTIVNI ISHOD, TRAJANJE TRUDNOĆE I NAČIN POROĐAJA POSLE HISTEROSKOPSKE METROPLASTIKE KOD PACIJENTKINJA SA INFERTILITETOM

Tofoski Gligor, Dimitrov Goran, Hadzi Lega Marija, Dzikova Elena

PHI University Clinic of Gynecology and Obstetrics, Medical Faculty, University "St. Cyril and Methodius" - Skopje, Republic of Macedonia

Uvod: Kongenitalne anomalije uterusa mogu negativno uticati na reproduktivni ishod, povećavajući broj neuspešnih trudnoća i ginekoloških komplikacija. Standardna, bezbedna i minimalno invazivna metoda za tretman korektibilnih kongenitalnih anomalija uterusa je histeroskopska metroplastika (HM).

Cilj studije je analiza reproduktivnog ishoda, trajanje trudnoće i način porođaja kod pacijentkinja sa infertilitetom, posle histeroskopske metroplastike.

Materijal i metode: Analizirali smo 48 pacijentkinja sa prethodnom istorijom abortusa, kod kojih je rađena histeroskopija u periodu od 01. 11. 2009. do 01. 05. 2013. godine, na Univerzitetskoj Klinici za ginekologiju i akušerstvo u Skoplju. Kod pacijentkinja kod kojih je dijagnostikovana urođena anomalija uterusa, rađena je histeroskopska metroplastika. Pacijentkinje i njihov reproduktivni ishod su praćeni tokom najmanje 2 godine nakon intervencije. Reproductivni ishod je praćen uzimajući u obzir stopu trud-

noća, gubitak fetusa (abortus) do 22. gestacione nedelje, stopu pretermijskih i termijskih porođaja, živorođenja i način porođaja. Statistička analiza je izvedena uz pomoć odgovarajućeg programa i vrednost intervala poverenja ($\pm 95\%$ CI) je uzeta kao statistički značajna za $p < 0,05$.

Rezultati: Posle histeroskopske metroplastike javio se značajan pad stope abortusa na 13,9%, i značajan porast stope trudnoća na 86,1%. Ukupna stopa trudnoća je bila 75%, a termijski porođaj je notiran kod 93,6% pacijentkinja, spontani porođaj kod 58,6%. Nije bilo komplikacija tokom histeroskopske metroplastike, niti tokom porođaja.

Zaključak: Histeroskopska metroplastika ima značajan uticaj na reproduktivni ishod, rezultirajući u značajnom broju živorođenja i bez značajnih komplikacija tokom konsektivne trudnoće i porođaja.

Ključne reči: histeroskopija, metroplastika, reprodukcija, infertilitet, trudnoća, porođaj.

REFERENCES

1. Speroff L, Glass RH, Kase NG. Development of the mullerian system. In: Mitchell C, eds. Clinical gynecologic endocrinology and infertility. 6th ed Baltimore, Md: Williams & Wilkins, Lippincott, 1998; p.124.
2. Fedele L, Bianchi S. Hysteroscopic metroplasty for septate uterus. *Obstet Gynecol Clin North Am.* 1995; 22(3): 473–89.
3. Raga F, Bauset C, Remohi J, Bonilla-Musoles F, Simon C, Pellicer A. Reproductive impact of congenital Mullerian anomalies. *Hum Reprod.* 1997; 12(10): 2277–81.
4. Chan Y.Y., Jayaprakasan, K., Zamora J, Thornton JG, Raine-Fenning N, Coomarasamy A. The prevalence of congeni-

tal uterine anomalies in unselected and high-risk populations: a systematic review. *Hum Reprod Update.* 2011; 17(6) 761–71.

5. Harger JH, Archer DF, Marchese SG, Muracca-Clemens M, Garver KL. Etiology of recurrent pregnancy losses and outcome of subsequent pregnancies. *Obstet Gynecol.* 1983; 62(5): 574–81.

6. The American Fertility Society classifications of adnexal adhesions, distal tubal obstruction, tubal occlusion secondary to tubal ligation, tubal pregnancies, mullerian anomalies and intrauterine adhesions. *Fertil Steril.* 1988; 49(6): 944–55.

7. Grimbizis G, Camus M, Tarlatzis BC, Bontis JN, Devroey P. Clinical implications of uterine malformations and hysteroscopic treatment results. *Hum Reprod Update.* 2001; 7(2): 161–74.

8. Grimbizis G, Camus M, Clasen K, Tournaye H, De Munck L, Devroey P. Hysteroscopic septum resection in patients with recurrent abortions or infertility. *Hum Reprod.* 1998; 13(5): 1188–93.
9. Pellicer A. Shall we operate Mullerian defects? An introduction to the debate. *Hum Reprod.* 1997; 12(7): 1371–2.
10. Jones HW Jr. Mullerian anomalies. *Hum Reprod.* 1998; 13(4): 789–91.
11. Homer HA, Li T, Cooke ID. The septate uterus: a review of management and reproductive outcome. *Fertil Steril.* 2000; 73(1): 1–14.
12. Šuster N, Gergolet M. Does hysteroscopic metroplasty for septate uterus represent a risk factor for adverse outcome during pregnancy and labor? *Gynecol Surg.* 2016; 13: 37–41.
13. McCarthy FP, Khashan AS, North RA, et al. Pregnancy loss managed by cervical dilatation and curettage increases the risk of spontaneous preterm birth. *Hum Reprod.* 2013; 28(12): 3197–206.
14. Messerlian C, Maclagan L, Basso O. Infertility and the risk of adverse pregnancy outcomes: a systematic review and meta-analysis. *Hum Reprod.* 2013; 28(1): 125–37.
15. Acien P. Reproductive performance of women with uterine malformations. *Hum Reprod.* 1993; 8(1): 122–6.
16. Buttram CV Jr. Mullerian anomalies and their management. *Fertil Steril.* 1983; 40(2): 159–63.
17. Heinonen KP, Saarikoski S, Postynen P. Reproductive performance of women with uterine anomalies. An evaluation of 182 cases. *Acta Obstet Gynecol Scand.* 1982; 61(2): 157–62.
18. Sendag F, Mermer T, Yucebilgin S, Oztekin K, Bilgin O. Reproductive outcomes after hysteroscopic metroplasty for uterine septum. *Clin Exp Obstet Gynecol.* 2010; 37(4): 287–9.
19. Nouri K, Ott J, Huber JC, Fischer EM, Stögbauer L, Tempfer CB. Reproductive outcome after hysteroscopic septoplasty in patients with septate uterus – a retrospective cohort study and systematic review of the literature. *Reprod Biol Endocrinol.* 2010; 8:52. doi: 10.1186/1477-7827-8-52.
20. Roy KK, Singla S, Baruah J, Kumar S, Sharma JB, Karmakar D. Reproductive outcome following hysteroscopic septal resection in patients with infertility and recurrent abortions. *Arch Gynecol Obstet.* 2011; 283(2): 273–9.
21. Goldenberg RL, Culhane JF, Iams JD, Romero R. Epidemiology and causes of preterm birth. *Lancet.* 2008; 371(9606): 75–84.
22. Sentilhes L, Sergent F, Berthier A, Catala L, Descamps P, Marpeau L. Uterine rupture following operative hysteroscopy. *Gynecol Obstet Fertil.* 2006; 34(11): 1064–70.
23. Kayem G, Raiffort C, Legardeur H, Gavard L, Mandelbrot L, Girard G. Specific particularities of uterine scars and their impact on the risk of uterine rupture in case of trial of labor. *J Gynecol Obstet Biol Reprod.* 2012; 41(8): 753–71.

Correspondence to / Autor za korespondenciju

Tofoski Gligor

University Clinic of Gynecology and Obstetrics

Vodnjanska 17, 1000 Skopje, Macedonia

E-mail: gtofoski@yahoo.com